

A New Method to Evaluate Linear Block at the Left Atrial Roof: Is It Reliable Without Pacing?

CAIHUA SANG, M.D., CHENXI JIANG, M.D., JIANZENG DONG, M.D., XINGPENG LIU, M.D., RONGHUI YU, M.D., DEYONG LONG, M.D., RIBO TANG, M.D., LINGYUN GAO, M.D., MAN NING, M.D., GANG CHEN, M.D., WEIJU LI, M.D., and CHANGSHENG MA, M.D.

From the Department of Cardiology, Center for Atrial Fibrillation, Beijing Anzhen Hospital, Capital Medical University, Beijing, China

A New Method to Evaluate Linear Block at the Left Atrial Roof. *Objective:* The present study aimed to evaluate a new method for validation of complete linear block at the left atrial (LA) roof.

Background: Linear lesions at the LA roof have been reported to improve the success rate of catheter ablation of atrial fibrillation (AF).

Methods: Complete linear block at the LA roof was evaluated in 31 patients after complete isolation of pulmonary vein antrum (PVA) using a simple method. We hypothesized that complete linear block of the LA roof could be confirmed during sinus rhythm if (1) a continuous line of double potentials could be recorded at the LA roof, and (2) the activation sequence along the posterior wall changed to caudocranial. The results of this method were compared with standard pacing techniques.

Results: Thirty-nine lines were assessed using this method: 8 before and 31 after achievement of complete conduction block. After validation of complete linear block at the LA roof, double potentials with a mean interpotential interval of 60 ± 13 ms were recorded in 25 patients and electroanatomical mapping of the left atrium showed the activation sequence of posterior wall changed to caudocranial in all 31 patients during sinus rhythm. The sensitivity, specificity, positive and negative predictive values of this method for validating complete linear block were 100%, 88.9%, 96.8%, and 100%, respectively.

Conclusion: A corridor of double potentials along the roof line and a caudocranial activation sequence along the posterior wall during sinus rhythm can indicate conduction block at the LA roof after PVA isolation. (*J Cardiovasc Electrophysiol*, Vol. 21, pp. 741-746, July 2010)

atrial fibrillation, atrial tachycardia, catheter ablation, double potentials

Introduction

At present, the main strategy for catheter ablation of paroxysmal atrial fibrillation (AF) is centered on isolation of the pulmonary veins (PVs).¹⁻⁴ Left atrial linear ablation is one method for modifying the substrate of AF.^{5,6} It has been reported that roof line ablation of the left atrium (LA) could significantly improve the ablation success rate from 69% to 87%.⁷ To evaluate complete block of the roof line, the classical electrophysiological technique is to pace at the left atrial appendage (LAA), demonstrating a corridor of widely spaced double potentials along the roof line and a caudocranial conduction sequence of the posterior LA.⁷ Bachmann's

bundle (BB) plays a dominant role in the interatrial propagation during sinus rhythm in the normal heart,^{8,9} and during sinus rhythm the role of the earliest activation site of the LA is comparable with that of pacing at the LAA. Therefore, we hypothesized that a complete linear block at the LA roof could be recognized during sinus rhythm using similar criteria to the classical pacing technique. In this study, we investigated whether this simplified method is reliable for validating the complete linear block at the LA roof without pacing.

Methods

Patients

Thirty-one patients with drug-refractory paroxysmal AF, aged between 18 and 80 years, were enrolled in this study (mean age of 58 ± 9 years, 19 men). The exclusion criteria included: left atrial diameter >55 mm, left ventricular ejection fraction (LVEF) $<35\%$, New York Heart Association (NYHA) functional classes III and IV, contraindications for anticoagulation, previous AF ablation or the presence of left atrial thrombus. Prior to ablation, all antiarrhythmic drugs, except amiodarone, were discontinued for at least 5 half-lives. Low molecular weight heparin was administered subcutaneously until ablation procedure day after a left atrial thrombus was excluded by transesophageal echocardiography (TEE). The study protocol was approved by the institutional ethics review committee. Written informed consent was obtained from all patients.

Drs. Caihua Sang and Chenxi Jiang are co-first authors of this paper.

This work was supported in part by grants from the National Science Foundation Council of China (No. 30670843) and Beijing Science Foundation Council (No. 7072024).

No disclosures.

Address for correspondence: Changsheng Ma, M.D., Department of Cardiology, Center for Atrial Fibrillation, Beijing Anzhen Hospital, Capital Medical University, 2 Anzhen Road, Chaoyang District, Beijing 100029, P. R. China. Fax: +86-10-6445-6078; E-mail: chshma@vip.sina.com

Manuscript received 8 July 2009; Revised manuscript received 16 November 2009; Accepted for publication 18 November 2009.

doi: 10.1111/j.1540-8167.2009.01689.x

Study Protocol

The ablation strategies were as follows: after circumferential pulmonary vein antrum (PVA) isolation guided by an electroanatomical mapping system, the LA activation sequence was mapped during sinus rhythm (cardioversion if AF or other atrial tachyarrhythmias persisted). Roof line ablation was then performed, the LA activation sequence was remapped and the linear block at the LA roof was subsequently evaluated during sinus rhythm. Finally, standard pacing techniques were used to identify whether or not linear block at the LA roof was actually achieved. In addition, all the patients underwent cavotricuspid isthmus (CTI) ablation with an endpoint of bidirectional isthmus block. In patients with spontaneous non-PV foci initiating AF during burst pacing, mapping guided ablation was performed. The endpoint of the procedure was noninducibility of any sustained atrial tachyarrhythmias by burst atrial pacing.

Electrophysiological Study and Ablation

The electrophysiological study and ablation procedure were performed under conscious sedation with continuous intravenous (i.v.) infusion of fentanyl and midazolam. A quadripolar catheter was positioned in the coronary sinus. One or two 8-French-long sheaths (SL1; St. Jude Medical, Minnetonka, MN, USA) were introduced into the LA using a modified Brockenbrough technique. The transseptal sheath was continuously flushed with heparinized saline (20 mL/h) to prevent potential risk of thrombus formation or air embolism and i.v. heparin was administered to maintain an activated clotting time of 300–350 seconds. After transseptal catheterization, a 3.5 mm cool saline-irrigated ablation catheter (Navi-Star Thermo-Cool™, Biosense-Webster Inc., Diamond Bar, CA, USA) compatible with the electroanatomic mapping system (CARTO™ XP, Biosense-Webster Inc.) was used for mapping and ablation. The left atrial geometry was reconstructed based on a venogram of the PVs and a computed tomography (CT) image of the LA, guided by the CARTO system. The initial circumferential isolation of the right PVA was performed first, followed by isolation of the left PVA. Radiofrequency (RF) ablation was carried out with the temperature set at 45°C, the energy out-

put at 35 W, and the saline irrigation speed at 17 mL/min until the following criteria for complete lesion formation were met: local potential amplitude was significantly decreased (>80%), local potential duration was markedly widened, or an accumulated ablation at the same site lasted for 20 seconds at the posterior wall or for 30 seconds at the anterior wall. The endpoint of initial circumferential PVA ablation was the continuity of circumferential lesions. If AF or other sustained atrial tachyarrhythmias persisted after initial circumferential PVA ablation, direct current cardioversion was performed to restore sinus rhythm. Then, either an ablation catheter¹⁰ or a circular mapping catheter (Lasso™, Biosense-Webster Inc.) was used to map the activation sequence within the PVA area, and the conduction gaps were ablated until complete electrical isolation was finally realized. Subsequently, activation mapping of the whole LA was performed with the CARTO system during sinus rhythm (Fig. 1).

Ablation of the LA roof was performed by the creation of a contiguous line of ablation lesions joining both superior PVs after complete electrical isolation of both PVAs. The same temperature, energy output, and saline irrigation speed were set as during PVA ablation. Local potential elimination or formation of double potentials during sinus rhythm denoted effective ablation. To perform this ablation, an ablation catheter was introduced through an 8-French-long sheath to achieve stability and to orientate the catheter tip toward the LA roof. It was safe and effective to use the technique described by Hocini *et al.*^{7,11,12} Ablation was performed from the encircling lesions at the left superior PVA, with the sheath and catheter assembly rotated clockwise posteriorly and dragged to the right superior PVA. Ablation was performed as cranially as possible at the LA roof to avoid ablation of the posterior wall and its risk of atrioesophageal fistula, as reported by Pappone and coworkers.¹³ Various manipulations of the catheter/sheath assembly were adopted to facilitate the optimal orientation for ablation.¹¹ The stability of the catheter was monitored during RF applications using local electrograms, intermittent fluoroscopy and the CARTO system. Electroanatomic mapping was used for real-time monitoring and for tagging the ablation sequence. After initial ablation was performed and linear lesions connecting the left and right PVA attained, the LA was remapped by the CARTO

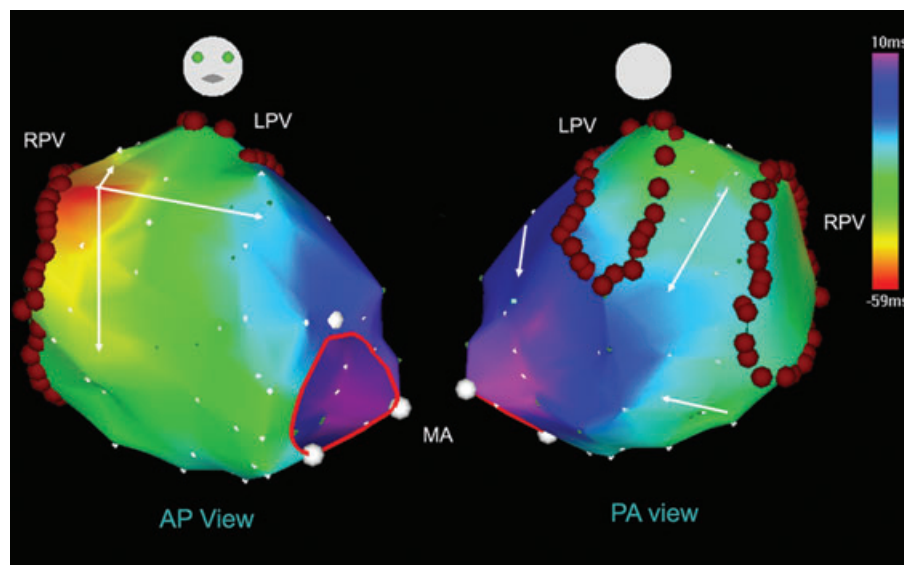


Figure 1. Electroanatomic activation map of the LA after PVA isolation during sinus rhythm. The earliest activation site occurred at the area of BB. Depolarization then spread septally and laterally and crossed the LA roof. The posteroanterior view of the CARTO image (right) shows a descending activation sequence along the posterior wall. AP = anteroposterior; PA = posteroanterior; LPV = left pulmonary veins; RPV = right pulmonary veins; MA = mitral annulus.

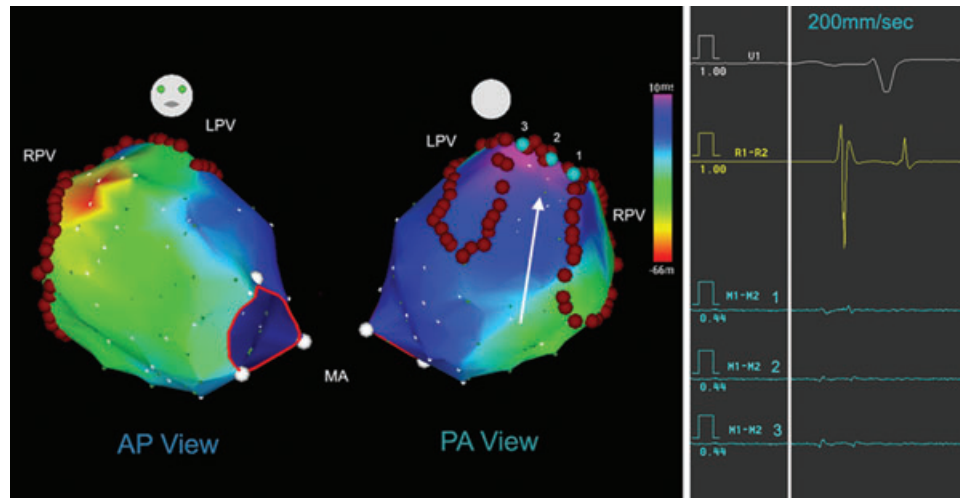


Figure 2. Activation pattern of the LA after roofline block was achieved in the same patient as shown in Figure 1. Posteroanterior view of the CARTO image showed that the activation sequence along the posterior wall changed to ascending and the latest activation site of the LA was located on the posterior side of the line. Double potentials were recorded along the linear lesions (points 1, 2, and 3). Abbreviations are as defined in the Figure 1 legend.

system during sinus rhythm to observe the whole LA activation pattern (Fig. 2). The electrophysiological endpoint of ablation was to achieve complete conduction block of the line joining the 2 superior PVs.

In all cases, the CTI was ablated, with the endpoint of bidirectional conduction block of the isthmus, and spontaneous non-PV foci were also ablated. The end point of the ablation procedure was noninducibility of any sustained atrial tachyarrhythmia (longer than 10 minutes) when burst atrial pacing from the distal CS (down to 180 ms or refractoriness) was initiated.

Evaluation of Linear Block at the LA Roof

We evaluated linear block at the LA roof during sinus rhythm using a simple method. After initial lesions at the LA roof were performed, we presumed that complete block was achieved if double potentials were recorded at various sites along the line and the conduction sequence on the posterior wall became caudocranial. The latter was affirmed with point-by-point sequential mapping by the CARTO system. Otherwise, detailed mapping along the lesion line was performed and the detected conduction gaps were ablated until the above-mentioned criteria were met. In some cases, double potentials could not be detected after intensive ablation but the caudocranial activation sequence along the posterior wall indicated that linear block had been achieved. After evaluating linear block of the LA roof, we then used standard electrophysiological techniques⁷ (LAA pacing, demonstrating widely spaced double potentials along the roof line and conduction detour) to assess the accuracy of this method.

Postablation Management

Unless contraindicated, all patients received 1 antiarrhythmic drug (as considered clinically appropriate) for 2 months after ablation and then discontinued if no AF recurred. All patients received warfarin anticoagulation, which was bridged with low molecular weight heparin. Warfarin was discontinued after 3 months if no AF was detected.

Statistical Analysis

Continuous variables are expressed as mean \pm standard deviation (SD) values. Comparisons were made by the Student's *t* test. A *P* value of <0.05 was considered significant.

Results

Ablation

Isolation of PVA, complete linear block of the LA roof and bidirectional CTI block were achieved in all 31 patients. Non-PV triggers of AF, localized at the superior cava vein, were also ablated successfully in 2 patients. No major complications such as PV stenosis, esophageal fistula, stroke or perforation and tamponade occurred in this study.

Characteristics of the LA Activation

In 26 patients, the earliest breakthrough sites of the LA were anatomically consistent with the areas of BB during sinus rhythm (Fig. 1). Depolarization spread septally and laterally and rapidly crossed the LA roof and then turned, descending to the posterior wall between the ostia of the left and right PVs. Breakthrough sites occurred at the margin of the fossa ovalis in 4 patients and coronary sinus ostial region in 1 patient. However, interatrial conduction was also via BB in all the 5 patients. The activation sequences along the posterior wall were descending in all 31 patients during sinus rhythm and changed to ascending in all the patients after linear block at the LA roof had been achieved (Fig. 2).

Evaluation of Linear Block at the LA Roof

The procedure duration and fluoroscopy time for ablation of the LA roof were 15 ± 7 minutes (range, 5–28 minutes) and 4 ± 2 minutes (range, 1–10 minutes), respectively. The range of RF energy delivery time was 2 to 27 minutes with a mean of 7 minutes. The length of the ablation lesions at the LA roof was 28 ± 14 mm (range, 8–50 mm), measured with the CARTO system.

TABLE 1

Evaluation of Linear Block at the LA Roof During Sinus Rhythm

	After Initial Ablation		After	Total
	Block	No Block	Complementary Ablation Block	
Lines	23	8	8	39
Double potentials	22	0	3	25
Caudocranial sequence of PW	23	1	8	32

N = 39 lines. The achievement of linear block was confirmed by LAA pacing techniques. LA = left atrium; PW = posterior wall.

To confirm whether complete linear block was achieved only during sinus rhythm, the criteria included double potentials recorded at various sites along the lesion line and the activation sequence along the posterior wall changing to caudocranial. After initial ablation, complete linear block was achieved in 23 patients. In 8 patients, complete block was achieved by mapping and ablating the gaps. Altogether, a corridor of double potentials along the lesion lines was recorded in 25 patients, in whom the activation sequence along the posterior wall changed to ascending (Table 1). The interpotential interval was 60 ± 13 ms (range, 41–90 ms), and the amplitude of the potentials was 0.38 ± 0.21 mV (range, 0.10–0.92 mV), both of which were measured at the mid-point of the line, using the CARTO system. During pacing at the LAA, the activation sequence on the posterior wall was descending in 1 patient, in whom no clear double potentials were detected along the lesions line, indicating persistent conduction across the roof. Complete block was achieved in this patient with complementary ablation.

In patients for whom complete linear block at the LA roof was achieved, the activation delays (compared with the earliest activation site of the LA) at the left and right extremes of the line were 87 ± 11 ms and 82 ± 9 ms, respectively, during sinus rhythm. During pacing at the LAA, the corresponding delays were 129 ± 13 ms ($P < 0.05$) and 135 ± 22 ms ($p < 0.05$), respectively.

The sensitivity, specificity, and positive and negative predictive values of this method to differentiate complete linear block of the LA roof were 100%, 88.9%, 96.8%, and 100%, respectively.

Discussion

The standard electrophysiological techniques to evaluate linear block at the LA roof have been introduced in detail by Hocini *et al.*⁷ In the present study, we introduced a new simple method to access complete linear block of the LA roof.

Activation Patterns of the LA During Sinus Rhythm

It has been reported that BB plays a very important role in the conduction between the right atrium (RA) and the LA during sinus rhythm.^{9,14} Several studies^{8,9} showed the earliest breakthroughs in the LA during sinus rhythm were located anatomically at the insertion site of the BB and the interatrial conduction could occur through other pathways simultaneously, such as the fossa ovalis or coronary sinus. In the present study, we found interatrial conduction was via BB in

all 31 patients during sinus rhythm, as previously reported.⁸ Some researchers^{14–16} showed that the earliest endocardial LA breakthrough during sinus rhythm also occurred on the posteroseptal wall adjacent to the ostia of the right PVs, the fossa ovalis, or the coronary sinus rather than the area of BB in some patients. Our study showed that the activation sequence along the posterior wall of the LA was always cranio-caudal during sinus rhythm, no matter where the earliest activation site was, which was similar to observations by Markides *et al.*¹⁵

Criteria for Identifying Linear Block of the LA Roof

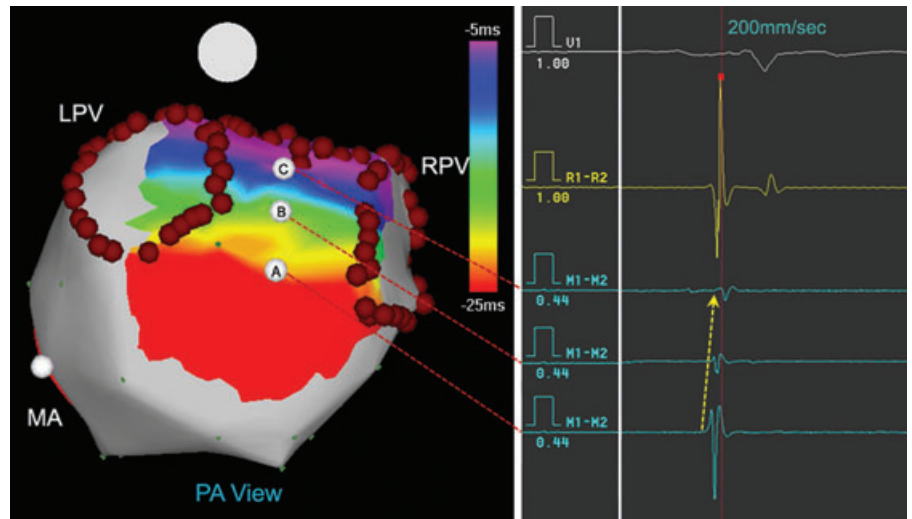
The standard electrophysiological techniques to differentiate complete linear block from persistent conduction at the LA roof include LAA pacing demonstrating widely spaced double potentials along the roof line and conduction detour.⁷ Because the earliest breakthrough site of the LA was located at the insertion site of BB during sinus rhythm in most patients, its role could be comparable with pacing at the LAA. Theoretically, complete conduction block can be achieved if widely split double potentials are recorded along the line and the activation sequence on the posterior wall changes to caudocranial during sinus rhythm. For the patients in whom clear double potentials were not detected, we considered that conduction block was actually achieved when the activation sequence of the posterior wall changed to ascending. In the present study, we observed that the amplitude of the potentials along the lesion was relatively low after ablation and double potentials were actually not recorded in 6 patients. This may be due to an area of electrical silence along the roof line, which resulted from extensive ablation.

Interatrial conduction may also occur over the muscular rim of the fossa ovalis and muscular fibers in the coronary sinus, including BB, so the accuracy of this method can be disputed. In this study, after achievement of complete linear block, the activation delays at the left and right extremes of the line during sinus rhythm were 87 ± 11 ms and 82 ± 9 ms, respectively, and the activation delay was prolonged during LAA pacing. The difference between the delays in these two methods may be due to simultaneous interatrial conduction via several pathways during sinus rhythm. In addition, the earliest activation site of the LA was different during sinus rhythm from that during pacing at the LAA. Of course, the activation sequence of the LA would not be affected by the normal conduction pathways between the double atriums during pacing at the LAA. However, we found other pathways had no influence on the activation sequence of the posterior wall, which changed to ascending after linear block was achieved at the LA roof during sinus rhythm. A single false positive case in this study may be due to slow conduction to the left of the lesion line and complete block was achieved after detailed mapping and ablation of the gaps. Another possibility is that conduction was recovered when pacing at the LAA. In summary, this method shows high sensitivity, specificity and both positive and negative predictive values.

Clinical Significance

The ablation procedure for AF, especially chronic AF, is complicated and challenging, with a long duration and high fluoroscopy exposure. In comparison with the classical techniques, the use of our proposed new method to evaluate linear

Figure 3. To recognize linear block with a simple mapping. After initial ablation, a simple mapping on the posterior wall was helpful to recognize whether or not linear block was achieved. The 3 points A, B, and C show a caudocranial activation sequence along the posterior wall which implies that complete block was achieved. Abbreviations are as defined in the Figure 1 legend.



block at the LA roof could simplify the process, reduce the procedure time and lower the risk of perforation at the LAA. In ablation practice, double potentials can be recorded after several RF applications during sinus rhythm and complete linear block could be confirmed with a simple mapping if the activation sequence on the posterior wall changes to caudocranial (Fig. 3). When this method is used to assess linear block at the LA roof of chronic AF patients, it should be considered that the LA activation pattern may change due to wide areas of ablation before sinus rhythm is restored.

Limitations

Firstly, we did not perform a detailed mapping of the LA activation patterns with relatively large samples. There may be some special interatrial conduction patterns during sinus rhythm that were not observed in our study. For most cases, however, this method is reliable.

Secondly, the polarity of the double potentials was not discussed in this paper, because it was difficult to manipulate the catheter and keep the tip in a consistency way for recording in each patient. In addition, bidirectional conduction block was not checked due to the difficulty of capturing the posterior wall.

Thirdly, it is not uncommon for ablation to be performed during AF. It is difficult to validate whether or not linear block is achieved during AF. The linear block cannot be confirmed until sinus rhythm is restored in patients with persistent or chronic AF.

Conclusions

We introduced a novel method to evaluate the linear block at the LA roof. Linear block at the LA roof can be confirmed after complete isolation of the PVA, if a corridor of double potentials is recorded along the lesion lines and if the activation sequence on the posterior wall changes to caudocranial during sinus rhythm. This new method is simple and reliable for validating the linear block at the LA roof.

References

1. Haissaguerre M, Jais P, Shah DC, Takahashi A, Hocini M, Quiniou G, Garrigue S, Le Mouroux A, Le Metayer P, Clementy J: Sponta-

- neous initiation of atrial fibrillation by ectopic beats originating in the pulmonary veins. *N Engl J Med* 1998;339:659-666.
2. Chen SA, Hsieh MH, Tai CT, Tsai CF, Prakash VS, Yu WC, Hsu TL, Ding YA, Chang MS: Initiation of atrial fibrillation by ectopic beats originating from the pulmonary veins: Electrophysiological characteristics, pharmacological responses, and effects of radiofrequency ablation. *Circulation* 1999;100:1879-1886.
3. Haissaguerre M, Shah DC, Jais P, Hocini M, Yamane T, Deisenhofer I, Chauvin M, Garrigue S, Clementy J: Electrophysiological breakthroughs from the left atrium to the pulmonary veins. *Circulation* 2000;102:2463-2465.
4. Arentz T, Weber R, Burkle G, Herrera C, Blum T, Stockinger J, Minners J, Neumann FJ, Kalusche D: Small or large isolation areas around the pulmonary veins for the treatment of atrial fibrillation? Results from a prospective randomized study. *Circulation* 2007;115:3057-3063.
5. Pappone C, Rosanio S, Augello G, Gallus G, Vicedomini G, Mazzone P, Gulletta S, Gugliotta F, Pappone A, Santinelli V, Tortoriello V, Sala S, Zangrillo A, Crescenzi G, Benussi S, Alfieri O: Mortality, morbidity, and quality of life after circumferential pulmonary vein ablation for atrial fibrillation: Outcomes from a controlled nonrandomized long-term study. *J Am Coll Cardiol* 2003;42:185-197.
6. Ernst S, Ouyang F, Lober F, Antz M, Kuck KH: Catheter-induced linear lesions in the left atrium in patients with atrial fibrillation: An electroanatomic study. *J Am Coll Cardiol* 2003;42:1271-1282.
7. Hocini M, Jais P, Sanders P, Takahashi Y, Rotter M, Rostock T, Hsu LF, Sacher F, Reuter S, Clementy J, Haissaguerre M: Techniques, evaluation, and consequences of linear block at the left atrial roof in paroxysmal atrial fibrillation: A prospective randomized study. *Circulation* 2005;112:3688-3696.
8. De PR, Ho SY, Salerno-Uriarte JA, Tritto M, Spadacini G: Electroanatomic analysis of sinus impulse propagation in normal human atria. *J Cardiovasc Electrophysiol* 2002;13:1-10.
9. Lemery R, Soucie L, Martin B, Tang AS, Green M, Healey J: Human study of biatrial electrical coupling: Determinants of endocardial septal activation and conduction over interatrial connections. *Circulation* 2004;110:2083-2089.
10. Dong J, Liu X, Long D, Yu R, Tang R, Lu F, Ma C: Single-catheter technique for pulmonary vein antrum isolation: Is it sufficient to identify and close the residual gaps without a circular mapping catheter? *J Cardiovasc Electrophysiol* 2009;20:273-279.
11. O'Neill MD, Jais P, Takahashi Y, Jonsson A, Sacher F, Hocini M, Sanders P, Rostock T, Rotter M, Pernat A, Clementy J, Haissaguerre M: The stepwise ablation approach for chronic atrial fibrillation—evidence for a cumulative effect. *J Interv Card Electrophysiol* 2006;16:153-167.
12. Knecht S, Hocini M, Wright M, Lellouche N, O'Neill MD, Matsuo S, Nault I, Chauhan VS, Makati KJ, Bevilacqua M, Lim KT, Sacher F, Deplagne A, Derval N, Bordachar P, Jais P, Clementy J, Haissaguerre M: Left atrial linear lesions are required for successful treatment of persistent atrial fibrillation. *Eur Heart J* 2008;29:2359-2366.
13. Pappone C, Oral H, Santinelli V, Vicedomini G, Lang CC, Manguso F, Torracca L, Benussi S, Alfieri O, Hong R, Lau W, Hirata K, Shikuma

- N, Hall B, Morady F: Atrio-esophageal fistula as a complication of percutaneous transcatheter ablation of atrial fibrillation. *Circulation* 2004;109:2724-2726.
14. Jurkko R, Mantynen V, Tapanainen JM, Montonen J, Vaananen H, Parikka H, Toivonen L: Noninvasive detection of conduction pathways to left atrium using magnetocardiography: Validation by intra-cardiac electroanatomic mapping. *Europace* 2009;11:169-177.
15. Markides V, Schilling RJ, Ho SY, Chow AW, Davies DW, Peters NS: Characterization of left atrial activation in the intact human heart. *Circulation* 2003;107:733-739.
16. Chang SL, Tai CT, Lin YJ, Wongcharoen W, Lo LW, Lee KT, Chang SH, Tuan TC, Chen YJ, Hsieh MH, Tsao HM, Wu MH, Sheu MH, Chang CY, Chen SA: The role of left atrial muscular bundles in catheter ablation of atrial fibrillation. *J Am Coll Cardiol* 2007;50:964-973.