

## Differentiating Atrioventricular Nodal Re-Entrant Tachycardia From Junctional Tachycardia Conflicting Responses?

Hongwu Chen, MD; Michael Shehata, MD; Eugenio Cingolani, MD; Sumeet S. Chugh, MD;  
Minglong Chen, MD; Xunzhang Wang, MD

Typical atrioventricular nodal re-entrant tachycardia (AVNRT) is the most common supraventricular tachycardia; however, junctional tachycardia (JT) is rare and occurs mostly in children or during infusion of isoproterenol.<sup>1,2</sup> Distinguishing between these arrhythmias can often be challenging during electrophysiology testing. They share many common characteristics, including similar intracardiac activation patterns, similar sites of earliest activation, and typical occurrence of a His bundle deflection before the atrial and ventricular electrograms. Slow pathway (SP) modification has evolved as the first-line treatment for AVNRT with acute success rates of 95% to 98%<sup>3,4</sup>; however, catheter ablation of JT has lower success rates and a higher rate of atrioventricular block.<sup>5</sup> Previous studies have suggested that premature atrial contractions (PACs) or atrial overdrive pacing can rapidly differentiate AVNRT from JT.<sup>2,6</sup>

---

**Editor's Perspective see p 236**

---

### Case Presentation

A 72-year-old woman with a history of paroxysmal supraventricular tachycardia that was refractory to medical therapy underwent catheter ablation. During the procedure, baseline AA interval during sinus rhythm, AH interval, and HV interval were 610, 80, and 38 ms (Figure 1A), respectively. Narrow QRS tachycardia was induced by atrial burst pacing (320 ms; Figure 1B), which was felt to be most consistent with slow/fast AVNRT (cycle length, 380 ms; AH, 340 ms; HA, 40 ms) based on the characteristics of induction with a critically long AH interval and the response to right ventricular overdrive pacing (Figure 1B and 1C). SP modification was performed and guided by intracardiac electrograms and fluoroscopic landmarks. After SP modification, a tachycardia spontaneously initiated during infusion of isoproterenol with a dosage of 1 µg/min at a cycle length of 540 ms, with HA and AH intervals of 40 and 500 ms, respectively, as illustrated in Figure 2A. The tachycardia could be terminated by rapid atrial pacing or PACs and would spontaneously initiate after a few sinus tachycardia beats (Figure 2A). Figure 2B demonstrates the spontaneous onset of tachycardia at faster sweep speed

with initial shortening of the HH interval to 450 ms, followed by tachycardia with the HH interval of 540 ms.

PACs were introduced throughout the diastolic interval beginning at 10 ms shorter than the tachycardia cycle length until the loss of atrial capture or tachycardia was terminated (Figure 2C). A PAC that advanced the immediate His by 50 ms resulted in delaying the subsequent His by 50 ms (Figure 2D). However, a later PAC advanced the immediate His by 40 ms, and there was no change in the following HH interval (Figure 2E). A later PAC delivered during His refractoriness advanced the following His by 15 ms, indicating that the mechanism of tachycardia was AVNRT (Figure 2F). This was confirmed multiple times with late-coupled PACs advancing the subsequent His activation without affecting the immediate His. Further ablation at the SP region was performed, and subsequently, no tachycardia could be induced with or without isoproterenol. At follow-up, 2 months after the procedure, there was no recurrence of symptomatic arrhythmia.

### Discussion

AVNRT is the most common regular supraventricular tachycardia, and catheter-based SP modification has become the first-line treatment strategy with a high success rate. Distinguishing AVNRT from JT is important after SP modification.<sup>3,4</sup> If the diagnosis is AVNRT, further SP modification is necessary to reduce the possibility of recurrence. If the diagnosis is JT, then further ablation may be avoided because of lower success rates and higher rates of possible atrioventricular block.<sup>5</sup> AVNRT and JT share many common characteristics, including clinical features, similar intracardiac activation pattern, similar sites of earliest activation, and negative ventricular-atrial intervals. However, the mechanisms of AVNRT and JT differ; with the former being re-entry and the latter usually enhanced normal automaticity.

Previous studies have reported methods to distinguish these 2 arrhythmias. Srivathsan et al<sup>7</sup> used differences in the HA interval during basal right ventricular pacing and tachycardia to distinguish AVNRT from JT. The delta HA was calculated as the HA interval during right ventricular pacing minus the HA interval during tachycardia. They found that a delta HA that was positive diagnosed JT with a sensitivity

---

Received July 31, 2014; accepted October 27, 2014.

From the Heart Institute, Cedars Sinai Medical Center, Los Angeles, CA (H.C., M.S., E.C., S.S.C., X.W.); and Cardiology Division, the First Affiliated Hospital of Nanjing Medical University, Nanjing, China (H.C., M.C.).

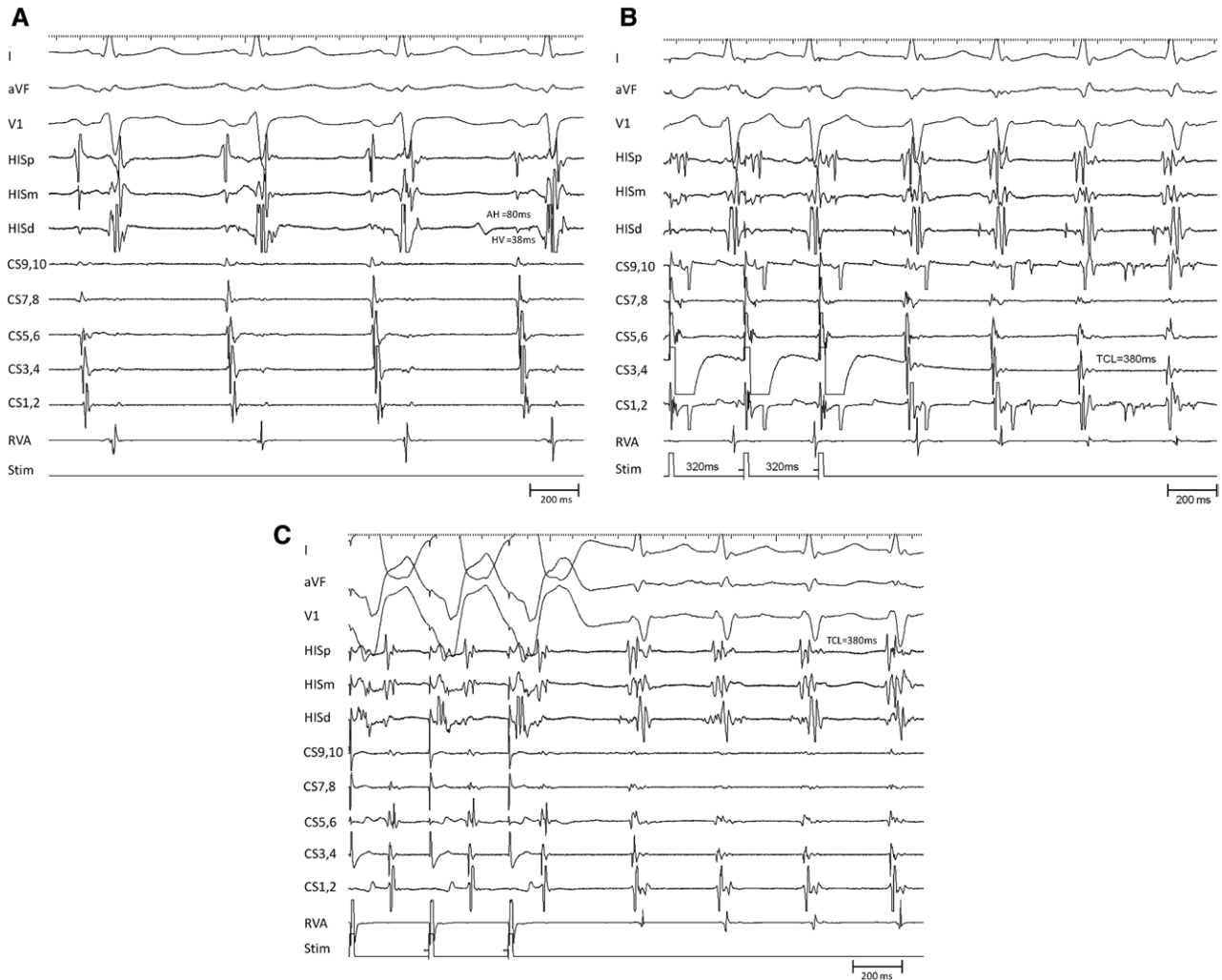
Correspondence to Michael Shehata, MD, Heart Rhythm Center, Heart Institute Cedars-Sinai Health System, Los Angeles, CA 90048. E-mail Michael.Shehata@cshs.org

(*Circ Arrhythm Electrophysiol*. 2015;8:232-235. DOI: 10.1161/CIRCEP.114.002169.)

© 2015 American Heart Association, Inc.

*Circ Arrhythm Electrophysiol* is available at <http://circep.ahajournals.org>

DOI: 10.1161/CIRCEP.114.002169



**Figure 1.** Baseline and tachycardia electrophysiological characteristics **A**, Baseline AA interval, AH interval, and HV interval were 610, 80, and 38 ms, respectively. **B** and **C**, Narrow QRS tachycardia was induced with coronary sinus pacing and diagnosed as typical atrioventricular nodal re-entrant tachycardia (cycle length=380 ms) by right ventricular overdrive pacing. CS indicates coronary sinus; and RVA, right ventricular apex.

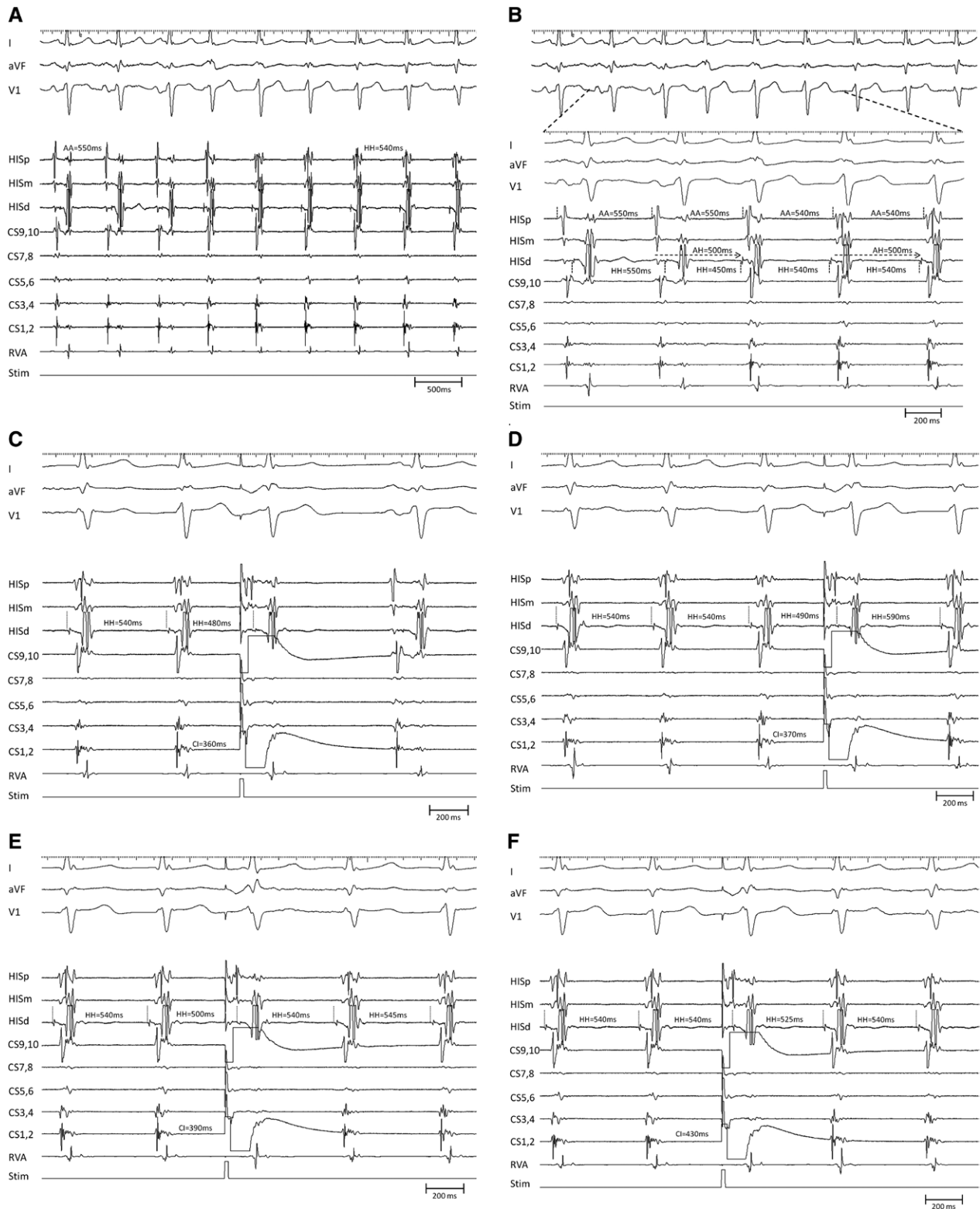
of 89% and a specificity of 83%; conversely, a negative delta HA diagnosed AVNRT with a sensitivity of 83%. A study by Padanilam et al<sup>6</sup> emphasized the significance of the different response to PACs during tachycardia. They postulated that any perturbation of the subsequent His during tachycardia, including advancement or delay, or termination of the tachycardia itself after a PAC delivered within the refractoriness of the His bundle indicates anterograde conduction via SP and can effectively exclude JT. To diagnose JT, they argued that advancement of the immediate His with continuation of the tachycardia had specificity for JT because AVNRT would be terminated in this scenario by introducing PACs before junctional depolarization. This finding would be true only in the absence of simultaneous anterograde fast and SP conduction.

In our case, a tachycardia spontaneously initiated during infusion of isoproterenol with a dosage of 1 µg/min at a cycle length of 540 ms after SP modification. Tachycardia was confirmed to be AVNRT by His refractory PACs (Figure 2F), but subsequent PACs delivered during the diastolic interval that advanced the immediate His with advancing or delaying the subsequent His may support JT as the mechanism (Figure 2D

and 2E). The conflicting responses to PACs delivered during tachycardia can only be explained by 1 atrial beat followed by 2 ventricular responses, suggesting anterograde conduction via the fast pathway and the SP with a longer AH interval. The AH interval of the first beat that initiates spontaneous tachycardia is 500 ms, which is identical to the AH interval during tachycardia, supporting the concept of 1 to 2 conduction at the onset of the arrhythmia (Figure 2B). We also speculated that at the onset of tachycardia, the third beat in Figure 2B is a fused atrial activation sequence by sinus and retrograde conduction, indicated by retrograde fast pathway activation at the distal His channel and sinus activation at the proximal His channel.

Termination of tachycardia with atrial overdrive pacing or PACs may have no benefit in differentiating the 2 arrhythmias because of overdrive suppression of JT or anterograde fast pathway conduction (Figure 2C).

The electrophysiological mechanism of this case can be summarized as follows: after SP modification, slower AVNRT mimicking JT was spontaneously initiated by 1 to 2 anterograde conduction and subsequent re-entrant tachycardia, and further ablation was necessary to eliminate tachycardia. In



**Figure 2.** Different responses to delivered premature atrial contractions (PACs) during tachycardia. **A**, The spontaneous initiation of tachycardia, note that the sinus and tachycardia cycle lengths are 550 ms and 540 ms, respectively (speed=50 mm/s). **B**, The second to sixth beat at faster sweep speed than **A**, note that the advanced His potential initiates the tachycardia (speed=100 mm/s). **C**, An early PAC advances the immediate His by 60 ms and terminates the tachycardia. **D**, PAC advances the immediate His by 490 ms and delays the next His by 590 ms. **E**, A late PAC advances the immediate His by 40 ms and there is no change in the subsequent His interval. **F**, The next His was advanced 15 ms by a PAC delivered during His refractoriness, which supports a mechanism of atrioventricular nodal re-entrant tachycardia. CS indicates coronary sinus; and RVA, right ventricular apex.

our opinion, it is critical to analyze each response to delivered PACs or atrial overdrive pacing during electrophysiology testing to avoid misdiagnosis or avoid unnecessary ablation.

### Disclosures

None.

### References

1. Rosen KM. Junctional tachycardia. Mechanisms, diagnosis, differential diagnosis, and management. *Circulation*. 1973;47:654–664.
2. Fan R, Tardos JG, Almasry I, Barbera S, Rashba EJ, Iwai S. Novel use of atrial overdrive pacing to rapidly differentiate junctional tachycardia from atrioventricular nodal reentrant tachycardia. *Heart Rhythm*. 2011;8:840–844. doi: 10.1016/j.hrthm.2011.01.011.
3. Jazayeri MR, Hempe SL, Sra JS, Dhala AA, Blanck Z, Deshpande SS, Avitall B, Krum DP, Gilbert CJ, Akhtar M. Selective transcatheter ablation of the fast and slow pathways using radiofrequency energy in patients with atrioventricular nodal reentrant tachycardia. *Circulation*. 1992;85:1318–1328.
4. Delise P, Sitta N, Zoppo F, Corò L, Verlato R, Mantovan R, Sciarra L, Cannarozzo P, Fantinel M, Bonso A, Bertaglia E, D'Este D. Radiofrequency ablation of atrioventricular nodal reentrant tachycardia: the risk of intraprocedural, late and long-term atrioventricular block. The Veneto Region multicenter experience. *Ital Heart J*. 2002;3:715–720.
5. Hamdan M, Van Hare GF, Fisher W, Gonzalez R, Dorostkar P, Lee R, Lesh M, Saxon L, Kalman J, Scheinman M. Selective catheter ablation of the tachycardia focus in patients with nonreentrant junctional tachycardia. *Am J Cardiol*. 1996;78:1292–1297.
6. Padanilam BJ, Manfredi JA, Steinberg LA, Olson JA, Fogel RI, Prystowsky EN. Differentiating junctional tachycardia and atrioventricular node re-entry tachycardia based on response to atrial extra-stimulus pacing. *J Am Coll Cardiol*. 2008;52:1711–1717. doi: 10.1016/j.jacc.2008.08.030.
7. Srivathsan K, Gami AS, Barrett R, Monahan K, Packer DL, Asirvatham SJ. Differentiating atrioventricular nodal reentrant tachycardia from junctional tachycardia: novel application of the delta H-A interval. *J Cardiovasc Electrophysiol*. 2008;19:1–6. doi: 10.1111/j.1540-8167.2007.00961.x.

KEY WORDS: atrial premature complexes ■ atrioventricular nodal tachycardia ■ junctional ectopic tachycardia